British Journal of Oral and Maxillofacial Surgery (1986) **24**, 332–341
© 1986 The British Association of Oral and Maxillofacial Surgeons

THE MANAGEMENT OF OSTEORADIONECROSIS OF THE JAWS

M. E. MORTON, F.D.S.R.C.S. and W. SIMPSON, F.D.S.R.C.S.
Department of Oral Surgery, Withington Hospital, Manchester

Summary. Therapeutic measures used in the management of osteoradionecrosis (ORN) of the jaws are reviewed with reference to clinical case material. The development of rational treatment regimes designed to deal with the underlying pathological problem are discussed.

Introduction

The incidence of osteoradionecrosis (ORN) of the jaws varies widely in the reported surveys, but appears to average at around 18%. Many factors relating to the tumour, the radiotherapy, and the dental status have been shown to influence the incidence (Rankow & Weissman, 1971; Murray *et al.*, 1980a; Morrish, 1981; Morton, 1986). ORN generally effects the mandible, occurring uncommonly in the maxilla.

ORN occurs when soft tissue integrity is lost and the radiation damaged bone is exposed in the mouth. The areas exposed are often extensive (Fig. 1). In other cases only a small area is exposed in the mouth (Fig. 2), but a radiograph is required to reveal the full extent of the bony destruction (Fig. 3). Loss of large portions of the mandible leads to considerable cosmetic deformity especially when the anterior part of the mandible is involved (Figs. 4 & 5).

Treatment of ORN falls into two categories: non-surgical and surgical, with many advocating a combined approach. Any consideration of the management of ORN would be incomplete without reference to prevention of this most destructive condition. In most studies the incidence of ORN in edentulous patients is lower than in dentate patients (Murray *et al.*, 1980a; Morrish, 1981). In our experience ORN in edentulous patients which is not related to previous extractions is often

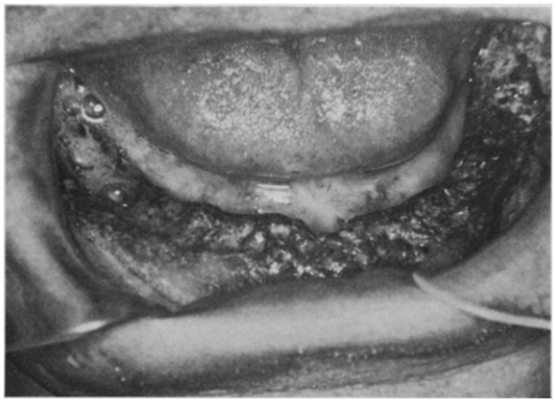

Fig. 1

Fig. 2

Figure 1—ORN affecting the whole mandible. Figure 2—Small area of ORN developing after extraction of a lower premolar.

(*Received* 18 December 1985; *accepted* 30 December 1985)

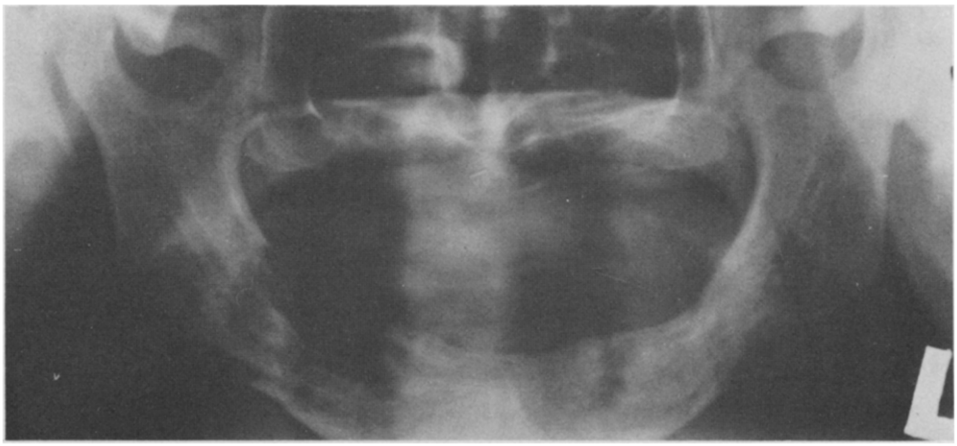

Fig. 3

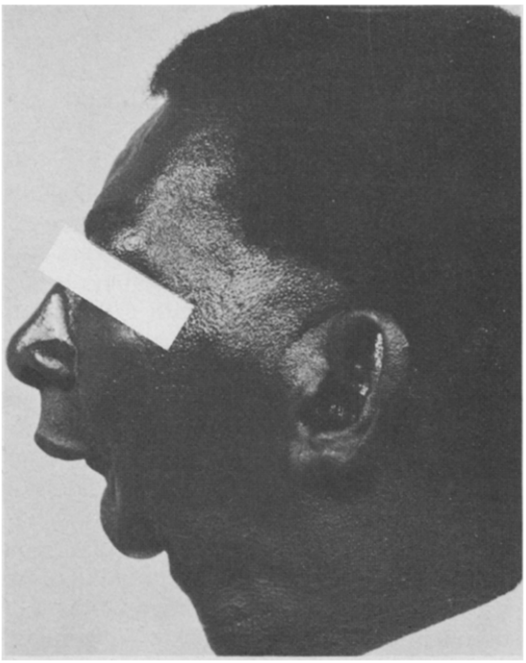

Fig. 4

Figure 3—Gross ORN seen on radiograph in a patient with only a small area of exposed bone in the mouth. Figure 4—Facial deformity caused by lack of the anterior mandible.

of a minor nature. The risk of extractions for patients who have had radiotherapy to the jaws is well known. The timing of extractions, the techniques used, and whether dental clearance is advisable are still matters of controversy (Morton, 1986). Murray (1980b) has shown the relationship between the presence of dental disease and the incidence of ORN. In a study of two groups of patients one of whom had received careful dental attention to eliminate dental disease there was a reduction

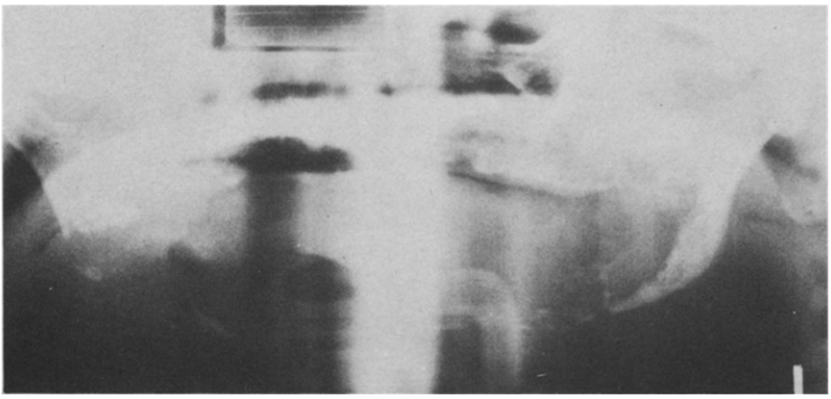

Figure 5—OPG of patient shown in Figure 4.

in incidence of ORN in the latter group although it was still not as low as the incidence for edentulous patients (Murray *et al.*, 1980a).

Treatment: a review of methods

(A) Non-Surgical

1. Change in life style: The patient is advised to give up alcohol and smoking, to avoid hot, cold, spicy or rough foods and to give up wearing dentures (Rankow & Weissman, 1971). As a short term measure to help a very small area of necrosis these measures may be useful in avoiding further trauma to the tissues. However, in the long term management of the patient with ORN, compliance with these instructions is often poor, and can only be considered as an adjunct to other therapy.

2. Topical treatment: Strict attention to oral hygiene is very important in helping to prevent secondary infection of the exposed area and preventing the incidence of further dental disease which will tend to exacerbate the condition. All dentate patients with ORN should see a hygienist regularly in addition to regular dental care.

Various types of mouthwash have been recommended and some authors suggest, in addition, regular gentle irrigation of the area. Our patients are supplied with a 10 ml syringe together with a filling quill to help in irrigation. Popular medicaments range from salt and sodium bicarbonate (Rankow & Weissman, 1971) to antiseptics such as chlorhexidine (Coffin, 1983). There is, however, some evidence that chlorhexidine when used for sites not directly associated with the teeth delays rather than promotes healing (Bassetti & Kallenberger, 1980). The use of packs over exposed bone has been popular in the past. MaComb (1962) used zinc peroxide mixed with carboxymethylcellulose in hydrogen peroxide, and also mentions the use of 5% neomycin solution or acriflavine as alternatives. In this unit we find packs are still useful especially for covering small areas of exposed bone and delicate granulation tissue following separation of a sequestrum. We also use packs for keeping necrotic bone cavities clean in patients who are not ready for definitive management. It is in both instances only a short term measure. We find BIPP (Bismouth & Iodoform paste) on ribbon gauze very satisfactory, as it remains fairly soft and stays quite clean. Figure 6 shows the radiograph of a very frail 75

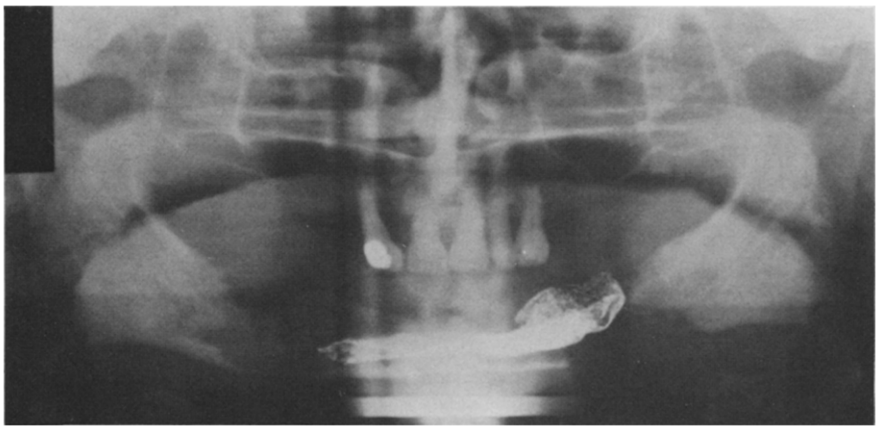

Fig. 6

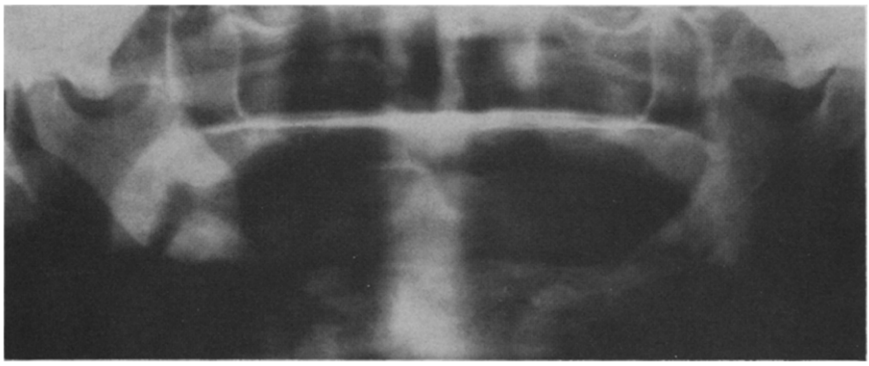

Fig. 7

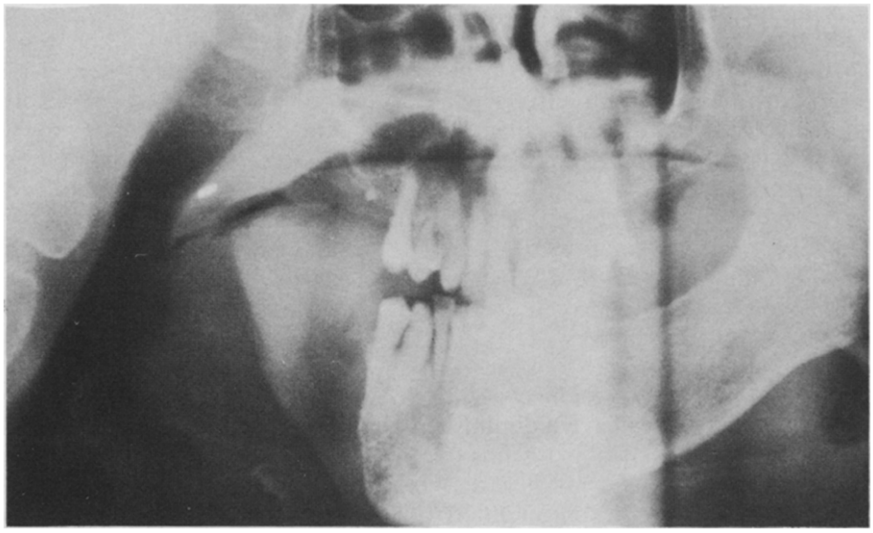

Fig. 8

Figure 6—OPG of a patient with severe ORN showing a BIPP dressing in place. Figure 7—OPG showing the condylar portion of the mandible displaced superiorly following loss of part of the horizontal ramus. Figure 8—OPG of a patient after partial mandibulectomy with disarticulation of the condyle.

year-old man who had undergone radiotherapy for an anterior floor of mouth squamous cell carcinoma 8 years previously. The ORN had been steadily progressive for 3 years. When seen in our unit his general condition was very poor and he was not considered fit for major surgical reconstruction. He was also unable to tolerate the hyperbaric oxygen chamber; however regular packing of the exposed bone gave him a degree of comfort and he learnt to do his own dressings.

3. Systemic Antibiotics: The role of antibiotics is far from clear. In many centres no clear distinction is made between septic and aseptic ORN. Rankow and Weissman (1971) give a 3 week course of a broad spectrum antibiotic such as tetracycline to all patients being treated conservatively. Rubin and Doku (1976) give penicillin 500 mg continued for as long as necessary. Coffin (1983) uses tetracycline, without sensitivity testing, 250 mg 6-hourly for 7 days then 8-hourly for 14 days and continues with 12-hourly doses until healed, which may be in excess of a year. Parulekar and Paonessa (1980) separate aseptic and septic cases and the latter are treated with high dose intravenous penicillin which is changed if the results of culture and sensitivity tests indicate. Marx (1983a), on examination of material from 25 consecutive cases of ORN, found that no organisms were present in the deep tissues but 75% of cases had surface organisms with candida species and streptococci predominating. Others have found the most frequently cultured organisms to include *Staph. aureus* and *albus*, *Strep. haemolyticus* and *viridans*, *Pneumococcus*, *Pseudomonas* and *E. Coli* (Mansfield *et al.*, 1981).

In our experience not all cases of ORN are infected and the use of long term antibiotics does not seem to be indicated. There is always the possibility of the development of resistant strains which should be avoided. However, a number of ORN cases are infected, and then the condition can become rapidly progressive and destructive and difficult to treat. The amount of necrotic tissue present and the poor vascularity of the surrounding tissue makes high antibiotic levels in the affected tissue difficult to achieve. It has been suggested that tetracycline would be suitable for use in ORN because of its attraction to bone, especially areas of new bone formation. However, tetracycline is bound in bone and the insoluble salt is probably inactive. When the tetracycline complex is resorbed it is likely that the local drug level is not increased to bacteriologically active levels (Ibsen & Urist, 1964). We use penicillin initially but change according to culture and sensitivity results, including culture for anaerobes. In addition to penicillin we find metronidazole with its spectrum of activity against anaerobes a useful antibiotic for these patients.

4. Hyperbaric Oxygen: Hyperbaric oxygen (HBO) therapy is probably the most recent advance in the management of ORN. In mandibular ORN its use has been described by Mainous *et al.* (1973), Mainous and Boyne (1974), Mainous and Hart (1975), Hart and Mainous (1976), Davis *et al.* (1979), Guernsey and Clark (1981), Mansfield *et al.* (1981) and Marx (1983b). It has also been used in the management of post-irradiation soft tissue necrosis (Greenwood & Gilcrist, 1973; Davis *et al.*, 1979). In ORN the basic lesion is a chronic non-healing hypoxic wound (Marx, 1983a). Irradiated tissues have a diminished ability to deal with trauma (McIndoe, 1947) and this is noted by all surgeons operating in pre-irradiated sites. Although hyperbaric oxygen does not produce an increased rate of healing in well perfused wounds it has been shown experimentally to have a favourable effect on the rate of healing of ischaemic wounds (Kivisaari & Niinikoski, 1975). It has been shown in experimental burns to stimulate angiogenesis (Ketchum *et al.*, 1970). There is also increased fibroblastic proliferation and collagen formation when wound pO_2 is intermittently raised to 20–30 mm Hg (Silver, 1969; Hunt & Pai, 1972). It has been

shown by Silver (1969) that the tissue pO_2 is raised above these levels during hyperbaric dives.

HBO therapy has been used in the management of (especially anaerobic) infections (Boerena & Groenweld, 1970; Ellis & Mandal, 1983), and also increases the bacterocidal action of leucocytes (McCord *et al.*, 1971; Hohn, 1977).

In the cases reported of the use of HBO in the treatment of ORN of the mandible, high success rates have been a feature. The regimes used are basically similar; 100% O_2 is breathed at 2–2.4 atmospheres for 90–120 min per day, 5 or 6 days per week for 8 weeks or more. Most authors also use intensive local measures, antibiotics and where indicated, surgery such as sequestrectomy. Marx (1983b) described a fairly rigid protocol with patients failing to respond within a limited time to simple HBO therapy moving on to simple surgery and then to resection and bone grafting. However in a report of four cases, Mainous *et al.* (1973) found surgery unnecessary and reported spontaneous resorption of sequestra.

In our unit we use a Vickers RHS3 single patient chamber. This unit, housed at the Regional Centre for Infectious Diseases, delivers 100% O_2 at 2 atmospheres. Patients are treated in the chamber for two, 2-h sessions per day, 5 days per week for 3 weeks. We have not noticed dramatic healing of large areas of exposed necrotic bone, but we have noticed a qualitative improvement in the granulation tissue at the margins of the defect after treatment.

Complications of hyperbaric oxygen therapy in our patients were few. The commonest was anxiety, associated with a feeling of claustrophobia when in the chamber. This was severe enough in one case for treatment to be discontinued. Symptoms of middle ear pressure were sometimes seen and one patient required insertion of grommets. The types of complications that have been seen in patients undergoing therapy at our Regional Centre have been listed by Ellis and Mandal (1983). It is difficult to see how HBO therapy alone could be expected to deal with large masses of necrotic tissue, and we feel that HBO should be considered in conjunction with a surgical approach in extensive cases. It has been reported that HBO therapy has been helpful in controlling the severe pain experienced by some ORN patients; this has also been our experience.

(B) Surgical

Surgical methods advocated in the treatment of ORN vary from simple sequestrectomy to hemimandibulectomy. While surgery aims to remove frankly necrotic tissue, unless measures are taken to improve vascularity, healing will often be problematical.

Hahn and Corgill (1967) proposed drilling holes from non-vital to vital bone to allow ingress of granulation tissue. It is now generally felt that unless radical resection is planned the surgery should be designed to create as little trauma to the bone as possible. Sequestrectomies should be delayed until the necrotic bone can be lifted free easily, leaving the delicate granulation tissue in the bed undamaged (Rankow & Weissman, 1971; Dolezal *et al.*, 1982).

Marx (1983b) advocates transoral alveolar sequestrectomy with primary mucosal closure as part of his combined HBO therapy and surgery protocol. In our experience formal mucosal closure after sequestrectomy is often difficult in view of the friable nature of the tissues. Raising local flaps to perform closure risks damage to the flap and hence the underlying bone.

Resection can vary in extent from small sections of affected mandible to hemimandibulectomy or even total mandibulectomy. Marchetta *et al.* (1967) drew

attention to the morbidity associated with the extraoral approach to resection and advocated an intraoral approach. Rankow and Weissman (1971) describe a technique for intra-oral hemimandibulectomy. The criteria for surgery are discussed by many authors but generally it is felt that severe, intractable pain is the primary reason for surgery. If the ORN fails to respond to conservative measures then a surgical approach should also be considered.

In our experience if a resection has been carried out in the posterior part of the horizontal ramus, or if disease and sequestrectomies have resulted in a continuity defect of the mandible, there is a tendency for the distal fragment to be displaced superiorly and medially. Figure 7 shows a later radiograph of the same patient as in Figure 3 which illustrates this displacement. It can be the cause of pain and discomfort and in one case we have seen ulceration in the tuberosity region of the maxilla. We therefore feel that if reconstruction of the defect is not planned then disarticulation of the condyle or removal of the mandible to a high level should be performed.

To achieve a good cosmetic and functional result some consideration must be given to reconstruction, although this is not essential in all cases. Figures 8 and 9 show the radiographic and facial appearance of a man who underwent resection of the right mandible with disarticulation of the condyle and primary closure of the soft tissues. Application of intermaxillary fixation for a period post-operatively for these patients reduces the tendency of the mandible to deviate. If reconstruction is considered advisable several techniques are now available. In 1978, Obwegeser and Sailer described their experience with intraoral resection and immediate recon-

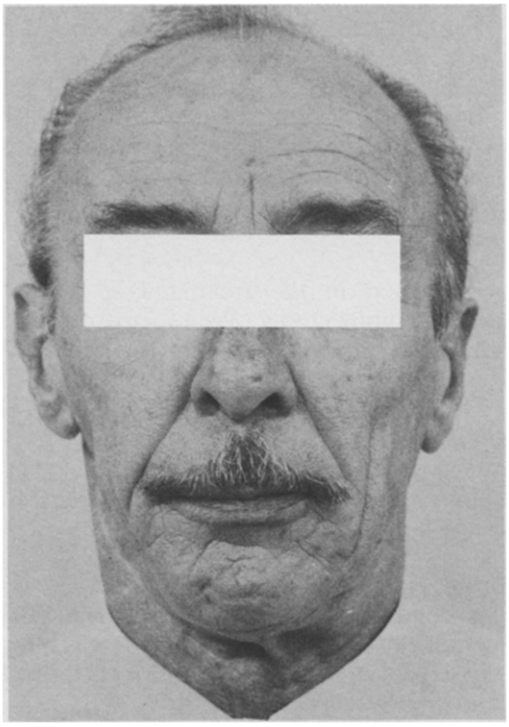

Figure 9—Facial appearance of the patient shown in Figure 8.

struction with iliac crest or rib bone grafts. In only two of their 10 cases was healing completely free of complication due to the poor quality of the soft tissues. Marx (1983b) described a technique whereby grafting was delayed for 10 weeks after the resection whilst the patient received hyperbaric oxygen. Although free bone grafts have been used in the past to reconstruct the mandible affected by ORN, with HBO therapy their success rate appears greatly improved. Perhaps vascularised compound flaps now offer the best results, as with HBO therapy, they address the basic underlying problem of reduced vascularity and reduced tissue viability. Figure 10 shows the radiograph of an elderly lady with ORN affecting the anterior part of the mandible resulting in pathological fracture. In this case bilateral nasolabial flaps were used to provide a thick vascular cover for the bone; a year later callus is clearly seen on the follow up radiograph (Fig. 11). The patient subsequently had a vestibuloplasty and now wears full dentures sucessfully. Dolezal *et al.* (1982) described the use of a deltopectoral flap to give vascularised soft tissue coverage, and a few weeks later a free bone graft was placed in the mandibular defect.

The development of microvascular techniques has led to the use of free osteocutaneous flaps which permit the one stage reconstruction and revascularisation of

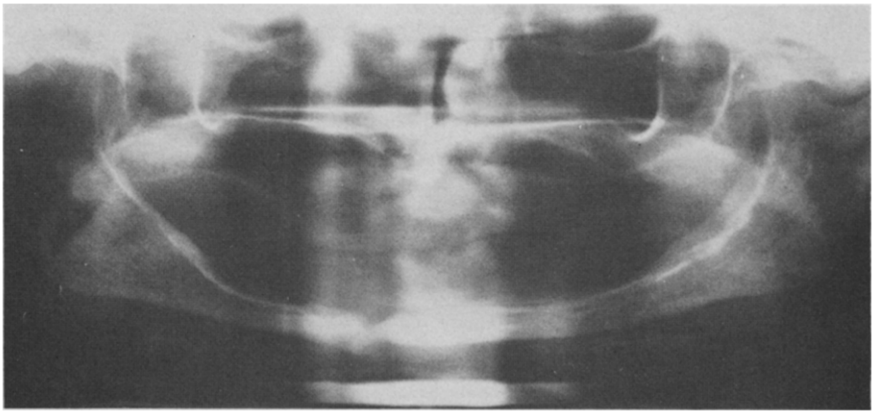

Figure 10—OPG showing pathological fracture of the mandible in a patient with ORN.

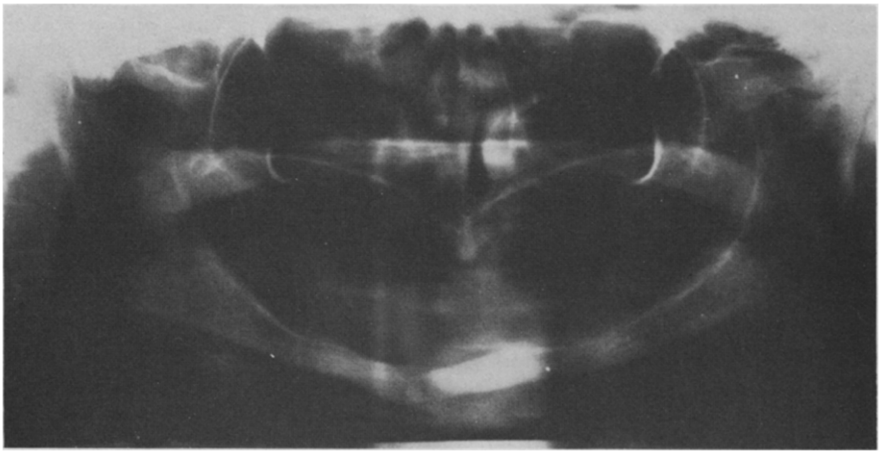

Figure 11—OPG of the same patient as in Figure 10 showing callus formation following nasolabial flaps.

the bone and soft tissues. In our unit we have a number of patients who have undergone such reconstruction with groin flaps. They have excellent cosmetic and functional results, and are able to wear dentures.

Discussion

All the methods of treatment reviewed here have their role in the management of this very difficult condition. We do not advocate a rigid treatment protocol, but feel that each case should be treated individually. It must be remembered that all these patients have undergone treatment for malignant disease. Many are elderly and in poor health. For many patients with severe ORN, major surgery aimed at providing new vascularised tissue appears to offer the best long term results. However, there are some patients for whom such surgery is inappropriate and these patients must be managed, often for many years, with a series of more conservative measures. We feel the use of HBO therapy presents many interesting possibilites, helping the basic underlying problem of hypoxic tissues; the combination of a moderate surgical procedure together with HBO therapy may well offer an alternative to major surgery for some of the less severely affected patients.

Prevention reduces the morbidity of ORN. The incidence has been shown to be reduced in patients who have a high level of dental care. If extractions have to be carried out they should be done with as little trauma as possible. It has been shown that minimal alveolectomy to remove all sharp bone and allow edge to edge closure of the socket reduces the incidence of ORN (Beumer *et al.*, 1972; Horiot *et al.*, 1981). Antibiotic cover is advisable. In experimental animals Alexander *et al.* (1967) showed that administration of tetracycline before extractions reduced the subsequent incidence of ORN.

Acknowledgement

We would like to thank the Department of Medical Illustration at Withington Hospital for their help.

References

Alexander, R., Elzay, R. P., Dettman, P. & King, E. R. (1967). Tetracyclines for controlling osteoradionecrosis in rat mandibles. *Journal of Oral Surgery*, **25**, 503.

Bassetti, C. & Kallenberger, A. (1980). Influence of chlorhexidine rinsing on the healing of oral mucosa and osseous lesions. *Journal of Clinical Periodontology*, **7**, 443.

Beumer, J., Silverman, S. & Benak, S. B. (1972). Hard and soft tissue necroses following radiation therapy for oral cancer. *Journal of Prosthetic Dentistry*, **27**, 640.

Boerema, I. & Groeneveld, P. H. A. (1970). Gas gangrene treated with hyperbaric oxygen. In Wada, J. & Iwa, T. (Eds.), *Proceedings of the Fourth International Congress on Hyperbaric Medicine*, p. 255. London: Baillière, Tindall & Cassell.

Coffin, F. (1983). The incidence and management of osteoradionecrosis of the jaws following head and neck radiotherapy. *British Journal of Radiology*, **56**, 851.

Davis, J. C., Dunn, J. M., Gates, G. A. & Heimbach, R. D. (1979). Hyperbaric oxygen: A new adjunct in the management of radiation necrosis. *Archives of Otolaryngology*, **105**, 58.

Dolezal, R. F., Baker, S. R. & Krause, C. J. (1982). Treatment of the patient with extensive osteoradionecrosis of the mandible. *Archives of Otolaryngology*, **108**, 179.

Ellis, M. E. & Mandal, B. K. (1983). Hyperbaric oxygen treatment: 10 years' experience of a Regional Infectious Diseases Unit. *Journal of Infection*, **6**, 17.

Greenwood, T. W. & Gilcrist, A. G. (1973). Hyperbaric oxygen and wound healing in post-irradiation head and neck surgery. *British Journal of Surgery*, **60**, 394.

Guernsey, L. M. & Clarke, J. M. (1981). Hyperbaric oxygen therapy with subtotal extirpation surgery in the management of radionecrosis of the mandible. *Inernational Journal of Oral Surgery*, **10**, Supplement 1, 168.

Hahn, G. & Corgill, D. A. (1967). Conservative treatment of radiation necrosis of the mandible. *Oral Surgery, Oral Medicine, Oral Pathology*, **24**, 707.

Hart, G. B. & Mainous, E. G. (1976). The treatment of radiation necrosis with hyperbaric oxygen. *Cancer*, **37**, 2580.

Hohn, D. C. (1977). Oxygen and leukocyte microbial killing. In David, J. C. & Hunt, T. K. (Eds.) *Hyperbaric oxygen therapy*. p. 101 Bethesda, Undersea Medical Society, Inc.

Horiot, J. C., Bone, M. C., Ibrahim, E. & Castro, J. R. (1981). Systematic dental management in head and neck irradiation. *International Journal of Radiation Oncology Biology and Physics*, **7**, 1025.

Hunt, T. K. & Pai, M. D. (1972). The effect of varying ambient oxygen tensions on wound metabolism and collagen synthesis. *Surgery, Gynecology and Obstetrics*, **135**, 561.

Ibsen, K. H. & Urist, M. R. (1964). The biochemistry and the physiology of the tetracyclines with special reference to mineralized tissues. *Clinical Orthopaedics and Related Research*, **32**, 143.

Ketchum, S. A. III., Thomas, A. N. & Hall, A. D. (1970). Angiographic studies of the effect of hyperbaric oxygen on burn wound revascularization. In Wada, J. & Iwa, T. (Eds.) *Proceedings of the fourth International Congress on Hyperbaric Medicine*, p. 388 London, Baillière, Tindal & Cassell Ltd.

Kivisaari, J. & Niinikoski, J. (1975). Effects of hyperbaric oxygenation and prolonged hypoxia on the healing of open wounds. *Acta Chirurgica Scandinavica*, **141**, 14.

MacComb, W. S. (1962). Necrosis in treatment of intraoral cancer by radiation therapy. *American Journal of Roentgenology*, **87**, 431.

Mainous, E. G., Boyne, P. J. & Hart, G. B. (1973). Elimination of sequestrum and healing of osteoradionecrosis of the mandible after hyperbaric oxygen therapy. *Journal of Oral Surgery*, **31**, 336.

Mainous, E. G. & Boyne, P. J. (1974). Hyperbaric oxygen in total rehabilitation of patients with mandibular osteoradionecrosis. *Journal of Oral Surgery*, **32**, 297.

Mainous, E. G. & Hart, G. B. (1975). Osteoradionecrosis of the mandible: Treatment with hyperbaric oxygen. *Archives of Otolaryngology*, **101**, 173.

Mansfield, M. J., Saunders, R. W., Heimbach, R. D. & Marx, R. E. (1981). Hyperbaric oxygen as an adjunct in the treatment of osteoradionecrosis of the mandible. *Journal of Oral Surgery*, **39**, 585.

Marchetta, F. C., Sako, K. & Holyoke, E. D. (1967). Treatment of osteoradionecrosis by intraoral excision of the mandible. *Surgery, Gynecology & Obstetrics*, **125**, 1003.

Marx, R. E. (1983a). Osteoradionecrosis: A new concept of its pathophysiology. *Journal of Oral and Maxillofacial Surgery*, **41**, 283.

Marx, R. E. (1983b). A new concept in the treatment of osteoradionecrosis. *Journal of Oral and Maxillofacial Surgery*, **41**, 351.

McCord, J. M., Keele, B. B. & Fridovich, I. (1971). An enzyme based theory of obligate anaerobiosis: The physiological function of superoxide dismutase. *Proceedings of the National Academy of Science U.S.A.*, **68**, 1024.

McIndoe, A. H. (1947). Symposium: Radiation Necrosis. *British Journal of Radiology*, **20**, 269.

Morrish, R. B., Chan, R., Silverman, S., Meyer, J., Fu, K. K. & Greenspan, D. (1981). Osteoradionecrosis in patients irradiated for head and neck carcinoma. *Cancer*, **47**, 1980.

Morton, M. E. (1986). Osteoradionecrosis: A study of the incidence in the North West of England. *British Journal of Oral and Maxillofacial Surgery*, **24**, 323.

Murray, C. G., Herson, J., Daly, T. E. & Zimmerman, S. (1980a). Radiation necrosis of the mandible: A 10 year study Part 1. Factors influencing the onset of necrosis. *International Journal of Radiation Oncology Biology and Physics*, **6**, 543.

Murray, C. G., Daly, T. E. & Zimmerman, S. (1980b). The relationship between dental disease and radiation necrosis of the mandible. *Oral Surgery, Oral Medicine, Oral Pathology*, **49**, 99.

Obwegeser, H. L. & Sailer, H. F. (1978). Experience with intraoral resection and immediate reconstruction in cases of radio-osteomyelitis of the mandible. *Journal of Maxillofacial Surgery*, **6**, 257.

Parulekar, S. S. & Paonessa, D. F. (1980). Septic osteoradionecrosis of the mandible. *Annals of Otolaryngology*, **89**, 383.

Rankow, R. M. & Weissman, B. (1971). Osteoradionecrosis of the mandible. *Annals of Otolaryngology*, **80**, 603.

Rubin, P. & Doku, H. C. (1976). Therapeutic radiology—the modalities and their effects on oral tissues. *Journal of the American Dental Association*, **92**, 731.

Silver, I. A. (1969). The measurement of oxygen tension in healing tissue. In Herzog, H. (Ed). *Progress in Respiratory Research*. p. 124. Basel, S. Karger.